

A Case Report of 2.5 Years Old, Male Child with Megalencephaly with Mental Retardation, Seizure Disorder, and GERD

Edwin Dias

Professor and HOD, Department of Pediatrics, Srinivas Institute of Medical Science and
Research Center, Mangalore, India
E-mail: dredwindias@gmail.com

Type of the Paper: Medical Case Study.

Type of Review: Peer Reviewed.

Indexed In: OpenAIRE.

DOI: <http://dx.doi.org/10.5281/zenodo.1212312>.

Google Scholar Citation: IJHSP

How to Cite this Paper:

Dias, Edwin. (2018). A Case Report of 2.5 Years Old, Male Child with Megalencephaly with Mental Retardation, Seizure Disorder, and GERD. *International Journal of Health Sciences and Pharmacy (IJHSP)*, 2(1), 8-12.

DOI : <http://dx.doi.org/10.5281/zenodo.1212312>.

International Journal of Health Sciences and Pharmacy (IJHSP)

A Refereed International Journal

© With Authors.



This work is licensed under a [Creative Commons Attribution-Non Commercial 4.0 International License](https://creativecommons.org/licenses/by-nc/4.0/) subject to proper citation to the publication source of the work.

Disclaimer: The scholarly papers as reviewed and published by the Srinivas Publications (S.P.), India are the views and opinions of their respective authors and are not the views or opinions of the SP. The SP disclaims of any harm or loss caused due to the published content to any party.

A Case Report of 2.5 Years Old, Male Child with Megalencephaly with Mental Retardation, Seizure Disorder, and GERD

Edwin Dias

Professor and HOD, Department of Pediatrics, Srinivas Institute of Medical Science and
Research Center, Mangalore, India
E-mail: dredwindias@gmail.com

ABSTRACT

A child of 2.5 years old had an intractable seizure, clinically had megalencephaly and mental retardation. On evaluation, video EEG showed fronto-central seizures and dysfunction R 1, scalp EEG showed bilateral paroxysmal bursts, MRI brain showed prominent vascular spaces in the hemisphere, GE reflux scan showed GERD. Other investigations were within normal limits. The child was treated with antiepileptics and antireflux measures and also rehabilitation.

Keywords: Megalencephaly, Mental retardation, Seizures, GERD.

1. INTRODUCTION :

Megalencephaly is the measurement of head circumference reported to be 2 standard deviations (SDs) above the age-related mean (1,2). Megalencephaly is defined as an increased growth of cerebral structures related to dysfunctional anomalies during the various steps of brain development in the neuronal proliferation and/or migration phases or as a consequence of postnatal abnormal events that cause excessive cerebral growth. A proper measure of the head circumference should be performed by putting the tape measure along the most prominent diameter of the occiput and the mid forehead; then, the results of the measurement must be checked with the head circumference growth charts, according to the age, gender, and height parameters [3].

2. CASE REPORT :

A Child of 2.5 years old male presents with delayed milestones, language and learning skills. History revealed Delayed motor and mental milestones as follows. Head control - 9/12, rolling over /Sitting 1 year not able to stand with support, 1 or 2 illegible words or sounds does not understand simple things told. Head size is big from the beginning. Now at 2 years, 9 months of age, he is able to stand with support, reaches out and exchanges objects

and makes bisyllables sounds. Hearing normal, now plays with toys. Delayed milestones revealed as the child is visually and auditory alert. He has the tactile awareness of different textures and shows attachment to both parents. He makes primary sounds to indicate his needs and responds when called. The process of play, communication, and social skills were decreased. He shows adequate visual engagement and participation in cause effect. He participates in water play and engages in play with large and brightly colored toys. He participates in group activities with other children. His repetitive behaviors reduced when engaged, cannot walk on own. When made to walk with support, eversion of the foot does not lift the foot, does not balance himself. No speech sometimes recognizes relatives. He used to have vomiting every time after taking food. Child had an episode of generalised tonic clonic seizure at 1 year 9 months of age. He was on sodium valproate but continued to have seizures, and medications were changed Carbamazepine (2mg/kg/day) and Clobazam. He continues to have episodes of tonic posturing followed by drowsiness, but the frequency of convulsions has increased. Seizure now getting 8-10 attacks in a days / once in 3-4 days, eye rolling, adduction and flexion of upper limb

lasting less than 1 minute. Natal and family history is not significant.

He was on following drugs for convulsion Syp.Tegretol, Clobazam, for 1 month but he continued to have seizures so he was changed to lamotrigine, Syp. Rantac twice daily. Syp.Keppra, Syp.Epilex for six weeks, Syp. Mosapride thrice daily, half an hour before meals. Even after all these medications, his seizure frequency not reduced. The child with a weight of 10.56 kg, height of 83.5 cm and with head circumference of 52cm. The child has the features Facial dysmorphism like broad forehead, down slanting palpebral tissue, low set ears, overriding of toes and Hypertelorism. There are 9 café-au-lait spots, the largest being 5x2cm. There are no neurofibromas. Plenty of café au lait spots left thigh and trunk. Pupils are equal and reacting to light. Hearing, Cranial nerve normal, vision – normal, Neck – normal. Developmental assessment of child with Left hand preference, when made to stand with support - unsteady, difficulty in lifting feet well, while lifting forefeet touches the ground. Stand with support when made to stand tone decreased DTR. Motor assessment Hypotonia in all limbs- UL is more than lower limb. Deep tendon reflexes are normal. Parachute reflex is complete Plantar withdrawal was observed.

3. INVESTIGATIONS :

CBC and S.Electrolyte were normal, EMG report shows normal nerve conduction parameter for child's age. THYROID STIMULATING HORMONE (TSH) within normal limits, Hemoglobinopathies sickle cell & other hemoglobinopathies within normal limits, USG Cranium shows normal Sonographic study of Brain.Video EEG is mild to moderately abnormal and the findings suggest Fronto Central Seizures and Dysfunction R1, and Right Fronto Temporal Seizures. Metabolic workup of the child shows Mucopolysaccharides were negative, Galactosemia uridytransferase within normal limit. Galactosemia, within normal limit, Acylcarnitine profile, Amino acid profile G6PD DNA analysis, CAH 17-OH, 17-Alphahydroxyprogesterone, Biotinidase within normal limits. GE REFLUX scan findings Positive for significant Gastroesophageal Reflux. No evidence of aspiration seen in the

lungs. Scalp EEG report Bilateral Paroxysmal Bursts on a poor Background, CT imaging of brain plain study CT Imaging does not reveal any obvious Abnormality in the brain parenchyma, Bony Skull or other observed structures. Multiplanar MRI of brain impression prominent vascular spaces are seen in Cerebral Hemispheres- which has been described in association with Mucopolysacchoridosis.

4. DISCUSSION :

In this child the metabolic workup result is negative, with neurological deficit, the case comes under anatomical cause. And there is no evidence of dwarfism or gigantism. So the diagnosis is megalencephaly within syndrome. Genetic work up could not be done because of refusal from parents, hence the diagnosis is not specific as to which genetic syndrome it belongs. Child continued to have seizures despite antiepileptic drugs. Rehabilitation measures were continued for mental retardation.

4.1 MEGALENCEPAHALY :

Fletcher [4] announced the term megalencephaly and with Wilson [5] defined this term is limited to children with cerebral overgrowth in association with neurological dysfunction [6]. Megalencephaly is classified etiologically Idiopathic or Benign, Metabolic, and Anatomic.

4.2 BENIGN OR IDIOPATHIC MEGALENCEPHALY :

Benign or idiopathic megalencephaly denotes children having an abnormally large head with nil neurological involvement.

4.3 METABOLIC MEGALENCEPHALY :

Inborn errors of metabolism may present with megalencephaly, Diagnosis is based on specific neurological clinical features related to megalencephaly. A metabolic disorder is suggested if familial history of similar disorders with a recessive hereditary inheritance, either autosomal or sex-linked or a history of marriages among relatives. A clearly progressive condition with more or less rapid neurological impairment, involving sometimes other organs, like the eyes, heart, spleen and liver, skin, and muscles along with increased intracranial pressure.

Examination in megalencephaly and metabolic disorders will demonstrate signs of

neurological impairment, large or tense fontanels, enlarged sutures, the sun-setting sign, hypotonia, irritability. In older children, neurodevelopment delay, lethargy, with or without seizures. Hepatosplenomegaly and/or other anomalous manifestations may hint to the diagnosis of neurometabolic disease. Laboratory diagnosis of metabolic impairment is accomplished through the demonstration of enzyme or chemical defect, which can be detected in serum, urine, cerebrospinal fluid, and tissue culture. Some of the affected children may expire before the head circumference ever reaches the maximum level. In association with megalencephaly Three groups of metabolic disorders like, defects of the organic acids, metabolic leukoencephalopathies or “metabolic encephalopathies”, and lysosomal storage diseases [2,4].

4.3 ANATOMICAL MEGALENCEPHALY :

Developmental megalencephaly is linked to a single gene mutation linking early brain cellular growth, migration, or replication. Mutation in the mammalian Target of Rapamycin (mTOR), mitogen-activated protein kinase, initially termed “extracellular signal-regulated kinases” (MAPK/ERK), and Sonic hedgehog (SHH) pathways reported frequently as pathogenetic events producing megalencephaly as a solitary anomaly along with additional body structural anomalies [2].

4.4 MEGALENCEPHALY WITHIN SYNDROMES :

Two syndromes, with megalencephaly which characterise a typical instance of anatomic brain overgrowth: megalencephaly–polymicrogyria–polydactily–hydrocephalus (MPPH) and megalencephaly-capillary malformation (MCAP). MPPH patients demonstrate De novo germline mutations in APT3 and PIK3R2. This syndrome is detected by abnormally increasing macrocephaly, attaining levels above 10 SDs. Ventriculomegaly progressing to hydrocephalus may occur along with cerebellar tonsillar ectopia, and polymicrogyria. Cutaneous lesions are complementary features comprising of capillary malformations and variable connective tissue dysplasia with Mild focal or segmental body overgrowth, finger or toe

syndactyly and postaxial polydactily can be observed [7]. MCAP has several signs overlapping the MPPH. MPPH shows several of the similar signs as the MCAP, plus the severe megalencephaly, except postaxial polydactily, which is common and more characteristic in the MPPA syndrome [8,9].

(i) Pretzel syndrome

Pretzel syndrome has an infantile-onset epilepsy, neurocognitive delay, craniofacial dysmorphism history of Polyhydramnios, megalencephaly, and symptomatic epilepsy syndrome (PMSE). Polyhydramnios is reported in about 80% of the cases reported frequently with this anomaly. The psychomotor disorders are associated with cognitive delay, early seizures, and hypotrophy of muscles. These children lie in a particular position named as “Pretzel-like posture.” Macrocephaly usually present in these children as stated by brain MRI is connected to the occurrence of extracerebral fluid or hydrocephalus in associated with disproportionate increased cerebral growth.

(ii) Other syndromes :

PTEN gene mutations have been detected in children with increased head circumference and autism spectrum disorder. Butler et al [10] reported 18 patients who had a germline PTEN mutation with X-linked intellectual disability, large head, and neurobehavioral findings of autistic spectrum disorder. These patients (13 males) demonstrated the head circumference increases to range from 2.5 to 8.0 SDs. Large head and autism are seen in patients with RAB1q mutation [4].

Congenital lipomatous overgrowth, vascular malformations, and epidermal nevi (CLOVE) syndrome present along with CNS malformations and seizures [11]. Gucev et al, [11] presented a newborn girl with massive lymphatic truncal vascular abnormality with the cutaneous venous anomaly, overgrown feet, and splayed toes. Cranial computed tomography (CT) exhibited encephalomalacia, widening of ventricles and sulci, and hemimegalencephaly. CLOVE syndrome and megalencephaly have also been stated [11], but megalencephaly is not an important sign of this syndrome.

Above is an algorithm for diagnosis of megalencephaly. Numerous congenital conditions and several molecular mutations

may cause megalencephaly, and in many of the cases, they are associated with other cerebral and clinical anomalies. The condition has to be distinguished by the macrocephaly that presents with different clinical situations.

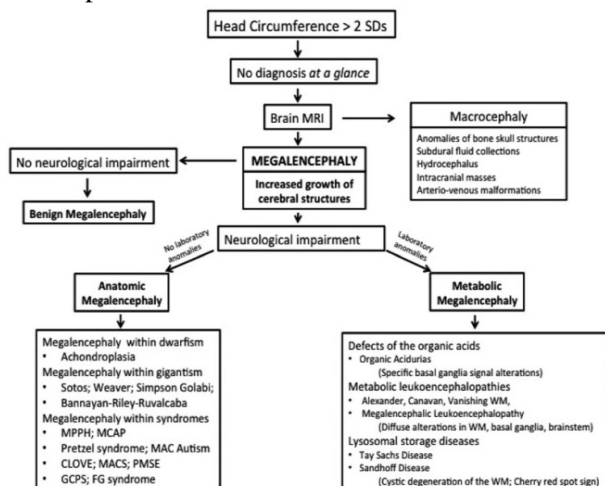


Figure 1: Diagnostic workup for increased head circumference in children.

5. CONCLUSION :

The diagnosis, follow up and treatment of MEGALENCEPHALY with mental retardation, with a seizure disorder, is often challenging. After a complete set of investigations, the root cause cannot be elucidated. In spite of all measures to treat the child, no improvement in either mental function or complete seizure control was achieved.

REFERENCES :

- [1] DeMyer W. Megalencephaly: types, clinical syndromes, and management. *Pediatr Neurol* 1986;2:321–8. [PubMed]
- [2] Winden KD, Yuskaitis CJ, Poduri A. Megalencephaly and macrocephaly. *Semin Neurol* 2015;35:277–87. [PubMed]
- [3] Sniderman A. Abnormal head growth. *Paediatric Rev* 2010;31:382-4.
- [4] Fletcher HM. A Case of Megalencephaly. Vol 51. 1900;London: Pathological Society of London, 230–232.
- [5] Wilson SAK. Megalencephaly. *J Neurol* 1937;14:193. [PMC free article] [PubMed]
- [6] DeMeyer W. Megalencephaly in children: clinical syndromes, genetic patterns, and differential diagnosis from other causes of megalencephaly. *Neurology* 1972;22:634–43. [PubMed]
- [7] Mirzaa GM, Poduri A. Megalencephaly and hemimegalencephaly: breakthroughs in molecular etiology. *Am J Med Genet C Semin Med Genet* 2014;166C:156–72. [PubMed]
- [8] Mirzaa G, Conway R, Graham JM, Jr, Dobyns WB. PIK3CA-related segmental overgrowth. In: Pagon RA, Adam MP, Ardinger HH, et al, editors. *SourceGeneReviews®* [Internet]. Seattle, WA: University of Washington; 1993–2015. [PubMed]
- [9] Mirzaa GM, Conway RL, Gripp KW, et al. Megalencephaly-capillary malformation (MCAP) and megalencephaly-polydactyly-polymicrogyria-hydrocephalus (MPPH) syndromes: two closely related disorders of brain overgrowth and abnormal brain and body morphogenesis. *Am J Med Genet A* 2012;158A:269–91. [PubMed]
- [10] Butler MG, Dasouki MJ, Zhou XP, et al. Subset of individuals with autism spectrum disorders and extreme macrocephaly associated with germline PTEN tumour suppressor gene mutations. *J Med Genet* 2005;42:318–21. [PMC free article] [PubMed]
- [11] Gucev ZS, Tasic V, Jancevska A, et al. Congenital lipomatous overgrowth, vascular malformations, and epidermal nevi (CLOVE) syndrome: CNS malformations and seizures may be a component of this disorder. *Am J Med Genet A* 2008;146A:2688–90. [PMC free article] [PubMed]